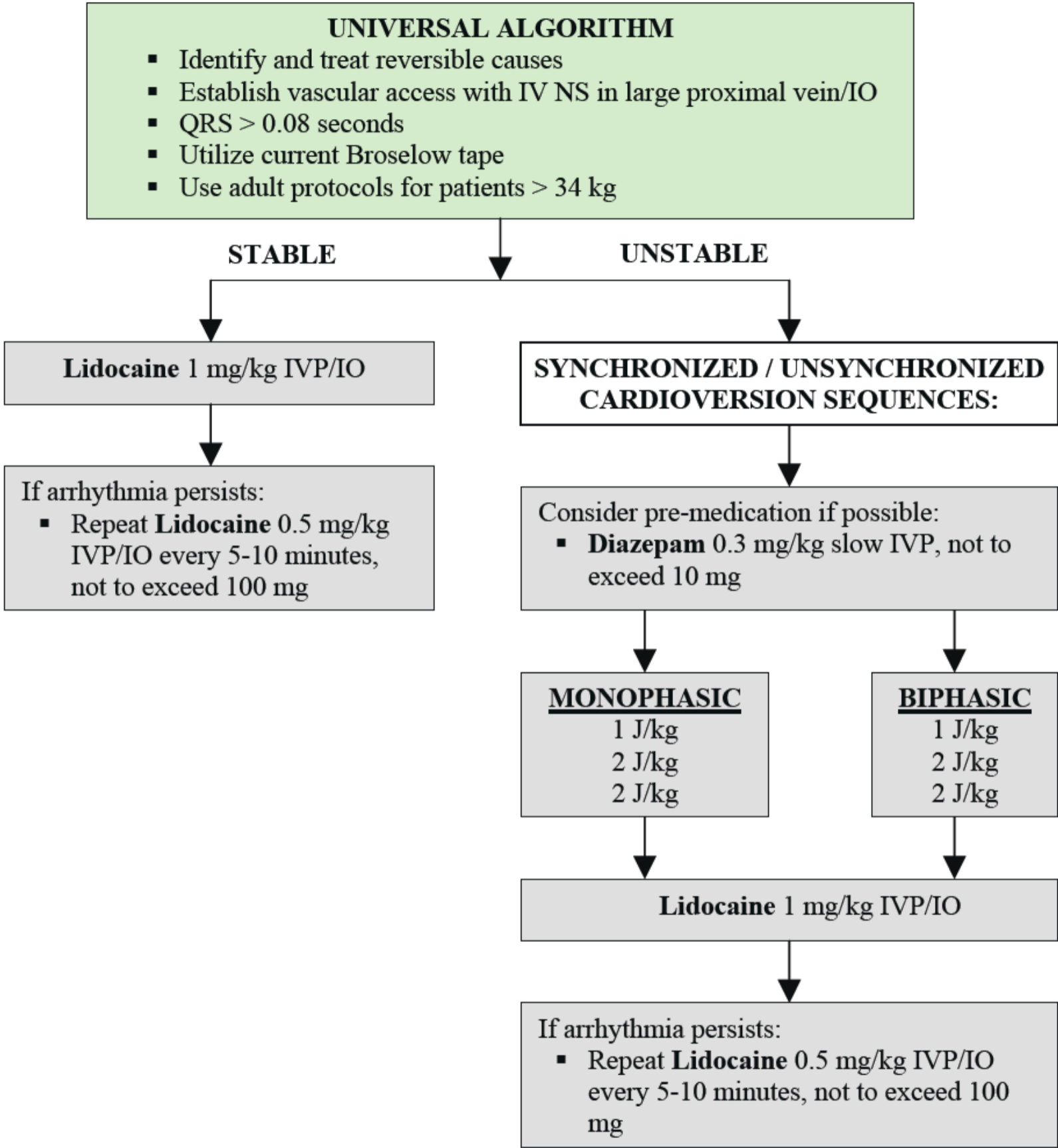


# PEDIATRIC VENTRICULAR TACHYCARDIA WITH A PULSE



- ### CONSIDERATIONS
- Vascular access may be omitted prior to cardioversion if in extremis.
  - If synchronized mode is unable to capture, then use unsynchronized defibrillation.
  - Obtain 12-lead EKG, if available, before and after cardioversion.
  - Notify base station for wide complex tachycardia (> 0.08 seconds).